

Copper-Associated Chronic Hepatitis in Labrador Retrievers

G. Hoffmann, T.S.G.A.M. van den Ingh, P. Bode, and J. Rothuizen

This study summarizes the clinical and pathologic findings in 15 Labrador Retrievers with copper-associated chronic hepatitis (CACH). Our hypothesis was that this form of hepatitis is caused by a defect in hepatic copper metabolism, which most likely originates from a genetic defect. Affected Labradors consisted of 11 female and 4 male Labrador Retrievers. Eight family members of 2 of these patients were examined prospectively, as were 6 unrelated healthy Labrador Retrievers. All dogs were registered at the breed club. The average age at clinical presentation was 7 years (range, 2.5–10.5 years). All dogs were presented for anorexia, which was associated with vomiting in 8 patients. The diagnosis of CACH was based on histologic examination of liver biopsy specimens in all dogs, including semiquantitation of copper. A disproportionate increase in alanine aminotransferase (ALT) activity relative to alkaline phosphatase (ALP) activity, as well as the centrolobular localization of copper and the association of copper accumulation with hepatic lesions, suggested a primary copper storage disease rather than primary cholestatic liver disease causing copper accumulation. Mean hepatic copper concentration measured in related Labradors was 1,317 $\mu\text{g/g}$ dry weight liver (range, 402–2,576 $\mu\text{g/g}$). Mean hepatic copper concentration of unrelated normal Labradors was 233 $\mu\text{g/g}$ dry weight liver (range, 120–304 $\mu\text{g/g}$). Our findings support the hypothesis that a hereditary form of hepatitis occurs in Labrador retrievers and is caused by a defect in hepatic copper metabolism.

Key words: Bedlington Terrier; Cirrhosis; Copper toxicosis; Hepatic zone 3; Metabolic disease; Wilson's disease.

Chronic hepatitis (CH) is a histologic diagnosis, characterized by the presence of fibrosis, inflammation, and hepatocellular apoptosis and necrosis. Cirrhosis can result as the end stage of the disease.¹ The term chronic hepatitis is used regardless of the cause of the disease, which usually is unknown in naturally occurring canine chronic hepatitis, although some cases have been associated with infections,² toxins,^{3–7} and hepatic copper accumulation. Hepatic copper accumulation can result from increased uptake of copper, a primary metabolic defect in hepatic copper metabolism, or from altered biliary excretion of copper. Inherited copper toxicosis is a well-described disease in the Bedlington terrier^{8,9} in which a deletion in the *COMMD1* gene (previously called *MURR1*) causes accumulation of copper in hepatocytes, resulting in chronic hepatitis. Moreover, hepatic copper storage and associated hepatitis seems to be breed-associated in the West Highland White Terrier,¹⁰ Skye Terrier,¹¹ Doberman Pinscher,¹² and Dalmatian.¹³

The Labrador Retriever often is affected by chronic hepatitis.¹⁴ Our objective was to summarize the clinical and pathologic findings in 15 Labrador Retrievers with copper-associated chronic hepatitis (CACH) and to investigate the possibility of a genetic basis of the disease by examination of family members from a line of Labradors with copper-associated chronic hepatitis.

From the Department of Clinical Sciences of Companion Animals (Hoffmann and Rothuizen), Department of Pathobiology (van den Ingh), Faculty of Veterinary Medicine, Utrecht University; and the Interfaculty Reactor Institute, Delft University of Technology, Netherlands (Bode).

Reprint requests: Gaby Hoffmann, DVM, Dipl. ACVIM, Dr med vet, Department of Clinical Sciences of Companion Animals, Faculty of Veterinary Medicine, Utrecht University, Yalelaan 8, P.O. BOX 80.154, 3508 TD Utrecht, Netherlands; e-mail: G.Hoffmann@vet.uu.nl.

Submitted October 17, 2005; Revised December 21, 2005; Accepted January 20, 2006.

Copyright © 2006 by the American College of Veterinary Internal Medicine

0891-6640/06/2004-0010/\$3.00/0

Materials and Methods

Affected Labrador Retrievers

The study population consisted of 15 consecutively identified Labrador Retrievers that had been diagnosed with chronic hepatitis or cirrhosis associated with increased copper concentrations that were registered at the Dutch Labrador Retriever breed club.^a The dogs were identified from the records of the diagnostic veterinary pathology service at the Faculty of Veterinary Medicine, University of Utrecht. All biopsy samples were evaluated by one of the authors (TvDI). Biopsy specimens from 11 of 15 dogs were obtained by our hepatology service at the University Clinic. Biopsy specimens from 4 dogs were obtained from private clinics. Clinical and clinicopathologic data were obtained from the medical records, as well as by telephone conversations with the veterinarians who managed the latter 4 dogs. Signalment, medical history, clinical examination findings, laboratory findings, histopathology, hepatic copper assessment, and the extraction method used for each liver biopsy specimen, as well as disease progression, were recorded. For comparative purposes, liver enzyme activities were reported as relative increase above the upper limit of the reference range. Pedigrees were obtained from the Dutch Labrador Retriever club.

Hepatic tissue was stained with rubeanic acid for evaluation of copper distribution and semiquantitation. A histochemical grading system previously applied to liver tissue from Bedlington Terriers with copper toxicosis and Doberman Pinschers with copper-associated hepatitis was used for semiquantitative evaluation of hepatic copper concentrations in all liver biopsy specimens.¹⁵ According to this grading system, copper scores >2 are abnormal.^b

Related Labradors and Normal Unrelated Labrador Retrievers

For 2 dogs with CACH, 8 of 17 identified family members from 3 different litters participated in the study. In order to obtain a healthy control group for comparison of hepatic copper concentrations, owners of 6 unrelated Labrador Retrievers agreed to participate in this study.

A medical history was obtained from all dogs ($n = 14$), and physical examinations were performed. Blood samples were collected in sodium citrate for analysis of a coagulation profile, including prothrombin time (PT), activated partial thromboplastin time (aPTT), and fibrinogen concentration. Blood was collected in heparin and EDTA for analysis of alkaline phosphatase (ALP), alanine aminotransferase (ALT), bile acids (BA), and platelet

count. Liver biopsy specimens were collected according to the Menghini technique described by Rothuizen.¹⁶ At least 3 liver biopsy specimens were taken from each dog. Two specimens were fixed in 10% neutral buffered formalin, and 1 biopsy was stored in a copper-free container for quantitative copper determination. Quantitative assay for copper in liver tissue was performed by neutron activation analysis according to a protocol described by Teske et al.¹⁷ using the facilities described by Bode.¹⁸ Quantitative copper concentrations were measured in lyophilized liver and reported in $\mu\text{g/g}$ dry weight liver (dwl).

The study was approved by the Utrecht University Institutional Animal Care and Use Committee. Owner consent was obtained for all dogs participating in this study.

Statistical Analysis

Statistical analysis was performed by use of commercially available software.^c A normal reference range was established from mean hepatic copper concentrations of 6 healthy dogs \pm 2 standard deviations. Because of small group sizes, a nonparametric statistical test was used for comparison between groups (Mann-Whitney test).

Results

Affected Labradors

Of 15 Labrador Retrievers with copper-associated chronic hepatitis, 2 dogs were related (dog 7 was the mother of dog 9). All dogs were registered at the breed club. The mean age at clinical presentation was 7 years (range, 2.5–10.5 years). Eleven dogs were females, including 3 spayed and 8 intact dogs, and 4 dogs were males, including 3 intact and 1 neutered Labrador. All dogs were evaluated between 1998 and 2002.

All dogs were presented for gastrointestinal signs, including anorexia in all and vomiting in 8 dogs. Clinical signs were acute in onset and progressive over several days ($n = 9$ dogs) to weeks ($n = 6$ dogs) before presentation to a veterinarian. Two dogs (dogs 2 and 9) presented 21 and 12 days after whelping. Three patients had a history of weight loss (dogs 3, 13, and 14), and 2 were reported as thin (dogs 3 and 14). Five dogs developed jaundice during the course of the disease (dogs 1, 5, 9, 12, and 14). Ascites was diagnosed in 2 patients (dogs 9 and 11), which had serum albumin concentrations of 1.8 and 2.3 g/dL. One patient (dog 4) had concurrent diabetes mellitus which was diagnosed 13 months before presentation and since that time was regulated with Caninsulin.^d IgG and IgM titers for *Leptospira* spp. were negative in 4 dogs. No exposure to potentially hepatotoxic drugs or exaggerated copper intake was reported.

The mean relative increase in ALT activity was 10.4 times the upper limit of the reference range (1–20.7 times above the upper reference value). The mean relative increase in ALP activity was 4.6 times the upper limit of the reference range (1.6–10.9 times above the upper normal value). In all but 1 patient (dog 10), the relative increase in ALT activity was greater than the relative increase in ALP activity. Five dogs had increased serum total bilirubin concentrations at initial presentation.

Mean serum albumin concentration was 2.8 g/dL (range, 1.8–3.4; normal range, 2.6–3.7 g/dL). Four

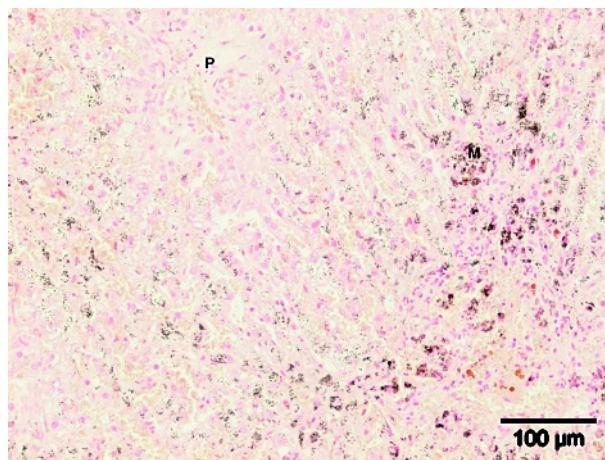


Fig 1. Rubanic acid-stained liver tissue of a patient with copper-associated chronic hepatitis, semiquantitative copper concentration = 3+ (normal <2+). M, pigment-laden macrophages; P, portal area.

patients had decreased serum albumin concentrations, <2.0 g/dL in 1 dog (dog 9: albumin, 1.8 g/dL).

In 2 dogs serum urea nitrogen concentration was below the normal range of 8.4 to 35 mg/dL (dogs 2 and 9). Blood ammonia concentrations were normal in both of these dogs. Serum glucose concentration was mildly increased in 1 dog (dog 9) and normalized during hospitalization.

Five of 12 dogs evaluated by coagulation profile had normal PT, aPTT, and fibrinogen concentrations. Isolated increases in aPTT were identified in 2 dogs (dogs 1 and 5), and an isolated increase in PT was identified in 1 patient (dog 8). Plasma fibrinogen concentrations were decreased in 5 patients (mean, 1.47 g/L; range, 0.5–3.3 g/L). These decreases were associated with prolonged PT (2 dogs), aPTT (1 dog), or prolonged PT and aPTT (2 dogs).

Red blood cell counts were within normal reference range in all 14 dogs evaluated. Five dogs had mild to moderate neutrophilic leukocytosis (mean white blood cell count, 14,000/ μL ; range 6,100–28,900/ μL).

Abdominal ultrasonography was performed in 12 dogs. The liver was of normal size in 5 of 12 dogs. In 6 dogs, the liver was small and located entirely within the rib cage. In 1 dog, the liver was mildly enlarged. Hepatic echogenicity and structure were normal in 9 of 12 patients. A hyperechoic liver and diffuse irregularities were seen in 3 dogs. In 4 patients, the liver was found to be normal for all 3 variables (ie, size, echogenicity, and structure). Ascites was present in 2 patients (dogs 9 and 11).

Liver tissue was obtained at postmortem examination (dogs 9, 12, 15), during laparotomy (dog 13), by ultrasound guidance (dogs 1, 2, 5, 7), or by the Menghini technique (dogs 3, 4, 6, 8, 10, 11, 14). Chronic hepatitis ($n = 11$), or CH with cirrhosis ($n = 4$) were associated with histologic evidence of copper accumulation in liver tissue of all patients. In all biopsy samples CH was characterized by varying degrees of hepatocellular

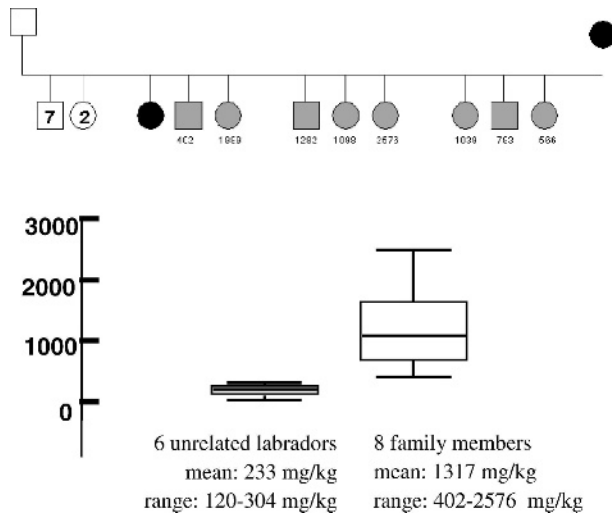


Fig 2. Above: Hepatic copper concentrations of 8 family members from 2 Labrador Retrievers with copper-associated chronic hepatitis. Pedigree: circle, female dog; square, male dog; small numbers depict the hepatic copper concentration in mg/kg dry weight liver; black, 2 former clinical patients with copper-associated chronic hepatitis; gray, examined family members; white, family members that did not participate in the study (2 female and 7 male offspring). Below: Box plots depicting the copper concentrations in liver tissue of 6 unrelated Labrador Retrievers (left) versus the 8 family members of patients with copper-associated chronic hepatitis (right).

apoptosis and necrosis, mononuclear inflammation, regeneration, and fibrosis. The severity of the hepatic inflammation was determined by the quantity of inflammation and extent of hepatocellular apoptosis and necrosis. Hepatitis was mild in 1 dog, moderate in 6 dogs, moderate to severe in 3 dogs, and severe in 5 dogs.

The stage of the disease was determined by the extent and pattern of fibrosis and the presence of cirrhosis. Liver architecture was normal in 6 dogs. Architectural distortion in liver tissue of 9 dogs included focal portal fibrosis (5), porto-central (2), centro-central (5), and dissecting fibrosis (2). Cirrhosis, characterized by regenerative nodules <3 mm in diameter, was diagnosed in 4 dogs (dogs 6, 9–11). Histologic features of cholestasis were present in biopsy specimens of 5 patients and graded as mild to moderate (dogs 6, 8, 9, 15) or severe (dog 1). Results of semiquantitative assessment of copper ranged from 2–3+ to 5+. Copper accumulated in zone 3 of the liver lobule (Fig 1) and was associated with inflammation in all biopsy samples.

Follow-up

Two dogs died and 7 affected Labradors were euthanized for signs attributable to their hepatic disease. The average time from initial presentation to death in these 9 dogs was 10.4 days (range, 1–50 days). None of these dogs had received copper-chelating medication, because early in the course of data collection Labrador Retrievers with chronic hepatitis were treated with

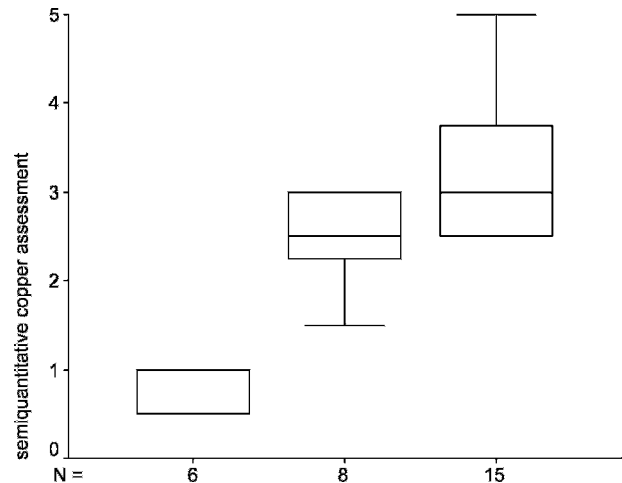


Fig 3. Box plots depicting the results from semiquantitative assessment of hepatic copper in 6 normal unrelated Labradors (left box), 8 related Labradors (middle box), and 15 affected Labradors with CACH (right box).

a standard therapy consisting of prednisolone.¹⁹ Because of histopathologic evidence of copper-related disease, penicillamine was added to the treatment regimen and finally applied as the sole medication. Clinical and histopathologic signs resolved with penicillamine therapy in 5 patients. Four of these 5 dogs received penicillamine exclusively (15 mg/kg PO q12h), and 1 dog received a combination of prednisolone (1 mg/kg PO q24h) and penicillamine (15 mg/kg PO q12h). One patient developed CACH 1 year after histologic cure and cessation of penicillamine treatment. The disease in this dog again was successfully controlled by reinstitution of penicillamine monotherapy.

Related Labradors

Five dogs were female and 3 were male. The average age was 4 years and ranged from 2 to 5 years. All dogs were clinically healthy and had no previous signs of hepatic disease. There was no evidence of exposure to drugs or possible exaggerated copper intake, and all affected dogs were fed commercial dog food. Serum activities of ALT, ALP, bile acid concentrations, coagulation profiles, and platelet counts were normal in all dogs. Histopathologic examination of liver biopsy samples identified the presence of copper localized in centrolobular hepatocytes. In 6 dogs, the liver was normal histologically. In 2 dogs, mild hepatitis was present, with periportal and central pigment-laden Kupffer cells and macrophages and moderate numbers of lymphocytes and plasma cells, as well as moderate numbers of copper granules. Results of semiquantitative assessment of copper were 1–2+ in the dog with a quantitative copper concentration of 402 $\mu\text{g/g}$ dwl, and ranged between 2–3+ and 3+ in the remaining dogs.

The mean quantitative hepatic copper concentration measured in the clinically healthy siblings and offspring was 1,317 $\mu\text{g/g}$ dry weight liver (range, 402–2,576 $\mu\text{g/g}$)

dwl), as shown in Figure 2. There was good agreement between quantitative hepatic copper concentrations and semiquantitative copper measurements in this group of dogs, which ranged from 1–2+ to 3+ (mean 2–3+; Fig 3). No difference was found between semiquantitative copper assessments in affected and related Labradors ($P = .084$).

Unrelated Normal Labradors

All dogs were clinically healthy and had no previous signs of hepatic disease. Three dogs were female, and 3 were male. The average age was 7.8 years and ranged from 5 to 10 years. Blood biochemistry and hematology were normal in all dogs. Results of histologic examination of liver were normal in 4 dogs. In 2 Labradors, mild nonspecific reactive changes of the liver were diagnosed. In these biopsy samples, the liver architecture was normal, but scattered pigment-laden macrophages and a few polymorphonuclear leukocytes were found in the liver parenchyma. Results of histologic assessment of copper ranged from negative to 1+. Quantitative hepatic copper concentration in this group of Labradors was 233 $\mu\text{g/g}$ dwl (range, 120–304 $\mu\text{g/g}$). A reference range for hepatic copper of <400 $\mu\text{g/g}$ dwl was established for these Labrador Retrievers (mean \pm 2 SD).

A Mann-Whitney test detected a difference between hepatic copper concentrations from normal dogs and related Labradors ($P = .001$).

Discussion

Inherited copper toxicosis is an autosomal recessive disease in the Bedlington Terrier⁸ in which a genetic mutation causes severe accumulation of copper in hepatocytes, resulting in chronic hepatitis. In addition to the Bedlington Terrier, hepatic copper storage seems to be breed-associated in the West Highland White Terrier, Dalmatian, Doberman Pinscher, and Skye Terrier. In the first 3 breeds, liver copper concentrations >2,000 $\mu\text{g/g}$ dwl have been reported.^{9–10,12} Copper concentrations in affected Skye Terriers range from 800 to 2,200 $\mu\text{g/g}$ dwl.¹¹

This report describes 15 Labrador Retrievers with chronic hepatitis associated with increased copper concentrations. Prospective examination of family members of these affected dogs identified subclinical hepatic copper accumulation (mean hepatic copper concentration of 1,317 $\mu\text{g/g}$ dwl; range, 402–2,576 $\mu\text{g/g}$ dwl).

In all but 1 of the affected dogs, serum ALT activity was increased, and ALP was above the upper limit of the reference range in all 13 dogs evaluated for ALP. Because the relative increase in ALT activity was greater than that of ALP (10.4 and 4.6 times normal, respectively), a primary hepatocellular liver disease was considered most likely. Serum total bilirubin concentration was increased in only 5 dogs. In addition, histopathology identified primary hepatitis and copper accumulation. Therefore, the cholestasis seen in some affected Labrador Retrievers was considered secondary.

The reference range for hepatic copper concentration in dogs is reported to be 100–450 $\mu\text{g/g}$ dwl.¹⁰ This is in agreement with the copper concentrations measured in liver biopsy specimens of normal Labradors in this study (range, 120–304 $\mu\text{g/g}$). In our study, there was no overlap between copper concentrations of normal unrelated Labradors and related Labrador Retrievers ($P = .001$). On the basis of the established normal range for hepatic copper in Labradors, some of the dogs in a previous study most likely had subclinical hepatic copper accumulation.²¹ In that study, copper concentrations between 140 and 915 $\mu\text{g/g}$ dwl were measured in 3 Labrador Retrievers without hepatitis (mean, 448 $\mu\text{g/g}$ dwl).²¹ The dogs of that study were identified because a related Labrador Retriever had liver disease. Because of a lack of additional detail on the hepatic disease of the related dog, it is not possible to compare those Labradors directly to our related Labradors. However, our finding of isolated accumulation of copper without development of hepatitis is in agreement with the previous results. Until the genetic defect underlying copper accumulation in Labradors is identified, we will not be able to explain why copper can accumulate without causing hepatitis in the Labrador Retriever. One investigator had followed dogs with the COMMD1 deletion from birth to 3 years of age, and copper accumulated in the liver by 1 year of age, whereas histologic signs of hepatitis did not occur before affected dogs were 2 years old (R. Favier, personal communication). Dogs with inherited copper storage disorders may therefore be subject to a prolonged delay period of several years between severe accumulation of copper and development of histologic signs of inflammation.

The storage of copper in its nontoxic form may occur in the Labrador, allowing copper to accumulate in the liver of related and affected dogs. Exhaustion of cellular systems that protect against oxidative damage by occasional free reactive copper, or an additional stress factor that affects other protective mechanisms of the liver cell, may be necessary for copper to cause hepatitis in affected dogs.

In our group of 15 affected Labradors, hepatic copper was assessed by a semiquantitative histochemical grading system. Semiquantitative copper concentrations were previously correlated to quantitative measurements in other dog breeds, in which semiquantitative hepatic copper scores of 2–3+ corresponded to a concentration of 300–2,000 $\mu\text{g/g}$ dwl in Doberman Pinschers, and semiquantitative scores between 3+ and 5+ corresponded to quantitative copper concentrations between 1,500 and 4,000 $\mu\text{g/g}$ dwl in Bedlington Terriers.^{15,20} Our present results show a similar correlation of histochemical staining and quantitative copper concentrations in the related Labradors. This finding is in agreement with previous studies, and there was no statistical difference between semiquantitations of copper in related and affected dogs ($P = .084$). Nevertheless, semiquantitation of copper remains a subjective assessment and lack of quantitative measurement of copper in the affected Labradors is a limitation of our study. We did not

measure quantitative copper concentrations retrospectively because liver biopsy samples were taken by different techniques and not specifically handled and stored for quantitative analysis of copper. Quantitation of copper by neutron activation analysis is susceptible to interference from metals as well as electrolytes. Therefore, biopsy specimen handling and storage should be standardized in order to allow comparison of results to a normal range. Our normal reference range for copper was established for biopsy samples that were taken by means of the Menghini technique, using sterile water (not 0.9% NaCl) as well as copper-free plastic containers for storage. In our opinion, interpretation of quantitative copper concentrations from paraffin-embedded liver tissue, taken by different techniques and stored under nonstandardized conditions, could be difficult and potentially misleading.

Copper accumulation is always localized centrolobularly in inherited copper storage disorders (eg, Bedlington Terrier copper toxicosis, Wilson's disease in humans, liver disease in Long-Evans Cinnamon rats). Therefore, localization of copper in the centrolobular region of the liver lobule in our Labrador Retrievers may be considered an indicator for primary copper accumulation. This disease is unlike secondary copper loading of liver cells during cholestasis and cholestasis, where copper is mainly restricted to the periportal parenchyma. In all biopsy samples of the investigated family members, hepatocytes that stained positive for copper were always localized in zone 3 (ie, centrolobular), and semiquantitative hepatic copper concentrations in this group of dogs ranged from 1+ to 3+ (mean, 2–3+). Although we were unable to investigate all members of the family of interest, the participating dogs represent a random sample of all 3 matings. Hepatic copper concentrations of all investigated members of this family were abnormal.

Our findings suggest that copper-associated chronic hepatitis is familial and most likely caused by an inherited genetic defect in the Labrador Retriever. The results of this study support prospective studies in larger populations, as well as molecular biologic studies concerning copper metabolism, to identify the possible genetic basis of the disorder.

Footnotes

^a Nederlandse Labardor Vereniging, Oosterbeek, Netherlands

^b 0: no copper, 1: solitary liver cells and/or reticulohistiocytic (RHS) cells containing some copper positive granules, 2: small groups of liver cells and/or RHS cells containing small to moderate amounts of copper positive granules, 3: larger groups or areas of liver cells and/or RHS cells containing moderate amounts of copper positive granules, 4: large areas of liver cells and/or RHS cells with many copper positive granules, 5: diffuse presence of liver cells and/or RHS cells with many copper positive granules

^c SPSS 11.0 for windows, 2001, SPSS Inc, Chicago, IL

^d Intervet International BV, Boxmeer, Netherlands

Acknowledgments

We thank the dog owners for their participation, the Dutch Labrador Retriever Club and the Dutch Kennel Club for their contributions, the veterinarians who managed the patients for contributing their clinical and clinicopathologic data, and students for their assistance. This study was supported by the WAL-THAM Centre for Pet Nutrition.

References

1. van den Ingh TSGAM, van Winkle T, Cullen JM, et al. Chapter 7: Morphological classification of parenchymal disorders of the canine and feline liver. In: Rothuizen J, Bunch SE, Charles JA, et al. Chronic hepatitis. WSAVA Standards for Histologic and Clinical Diagnosis of Canine and Feline Liver Disease. Philadelphia, PA: Elsevier Churchill Livingstone; 2006:85–101.
2. Adamus C, Buggin-Daubie M, Izembart A, et al. Chronic hepatitis associated with leptospiral infection in vaccinated beagles. *J Comp Pathol* 1997;117:311–328.
3. Newberne PM. Chronic aflatoxicosis. *J Am Vet Med Assoc* 1973;163:1262–1267.
4. Chaffee VW, Edds GT, Himes JA, Neal FC. Aflatoxicosis in dogs. *Am J Vet Res* 1969;30:1737–1749.
5. Bunch SE, Castleman WL, Hornbuckle WE, et al. Hepatic cirrhosis associated with long-term anticonvulsant drug therapy in dogs. *J Am Vet Med Assoc* 1982;181:357–362.
6. Dayrell-Hart B, Steinberg SA, Van Winkle TJ, et al. Hepatotoxicity of phenobarbital in dogs: 18 cases (1985–1989). *J Am Vet Med Assoc* 1991;199:1060–1066.
7. Poffenbarger EM, Hardy RM. Hepatic cirrhosis associated with long-term primidone therapy in a dog. *J Am Vet Med Assoc* 1985;186:978–980.
8. van de Sluis B, Rothuizen J, Pearson PL, et al. Identification of a new copper metabolism gene by positional cloning in a purebred dog population. *Hum Mol Genet* 2002;11:165–173.
9. Twedt DC, Sternlieb I, Gilbertson SR. Clinical, morphologic, and chemical studies on copper toxicosis of Bedlington Terriers. *J Am Vet Med Assoc* 1979;175:269–275.
10. Thornburg LP, Shaw D, Dolan M, et al. Hereditary copper toxicosis in West Highland White Terriers. *Vet Pathol* 1986;23:148–154.
11. Haywood S, Rutgers HC, Christian MK. Hepatitis and copper accumulation in Skye Terriers. *Vet Pathol* 1988;25:408–414.
12. Mandigers PJ, van den Ingh TSGAM, Bode P, et al. Association between liver copper concentration and subclinical hepatitis in Doberman Pinschers. *J Vet Intern Med* 2004;18:647–650.
13. Webb CB, Twedt DC, Meyer DJ. Copper-associated liver disease in Dalmatians: A review of 10 dogs (1998–2001). *J Vet Intern Med* 2002;16:665–668.
14. Andersson M, Sevelius E. Breed, sex, and age distribution in dogs with chronic liver disease: A demographic study. *JSAP* 1991;32:1–5.
15. van den Ingh TSGAM, Rothuizen J, Cupery R. Chronic active hepatitis with cirrhosis in the Doberman Pinscher. *Vet Q* 1988;10:84–89.
16. Rothuizen J. Diseases of the liver and biliary tract. In: Dunn J, ed. *Textbook of Small Animal Medicine*. Philadelphia, PA: WB Saunders; 1999:448–497.
17. Teske E, Brinkhuis BGAM, Bode P, et al. Cytological detection of copper for the diagnosis of inherited copper toxicosis in Bedlington terriers. *Vet Rec* 1992;131:30–32.
18. Bode P. Instrumental neutron activation analysis in a routine way. *Journal of Trace and Microprobe Techniques* 1990;8:139.

19. Center SA. Chronic hepatitis, cirrhosis, breed-specific hepatopathies, copper storage hepatopathy, suppurative hepatitis, granulomatous hepatitis, and idiopathic hepatic fibrosis. In: Guilford AG, Center SA, Strombeck DR, et al, eds. *Strombeck's Small Animal Gastroenterology*, 3rd ed. Philadelphia, PA: WB Saunders; 1996:705–742.
20. Johnson GF, Gilbertson SR, Goldfischer S, et al. Cytochemical detection of inherited copper toxicosis of Bedlington Terriers. *Vet Pathol* 1984;21:57–60.
21. Thornburg LP, Rottinghaus G, McGowan M, et al. Hepatic copper concentrations in purebred and mixed-breed dogs. *Vet Pathol* 1990;27:81–88.